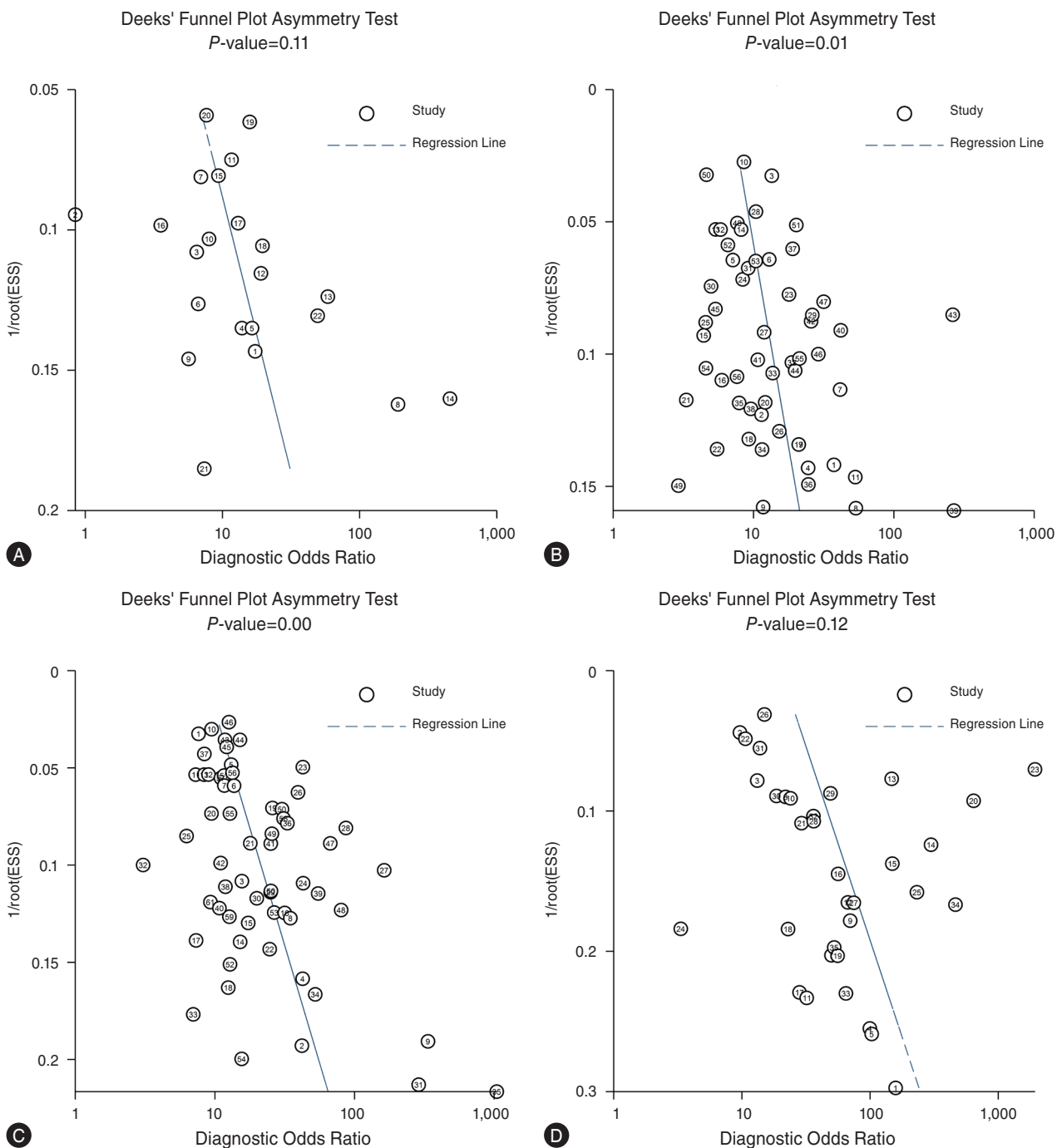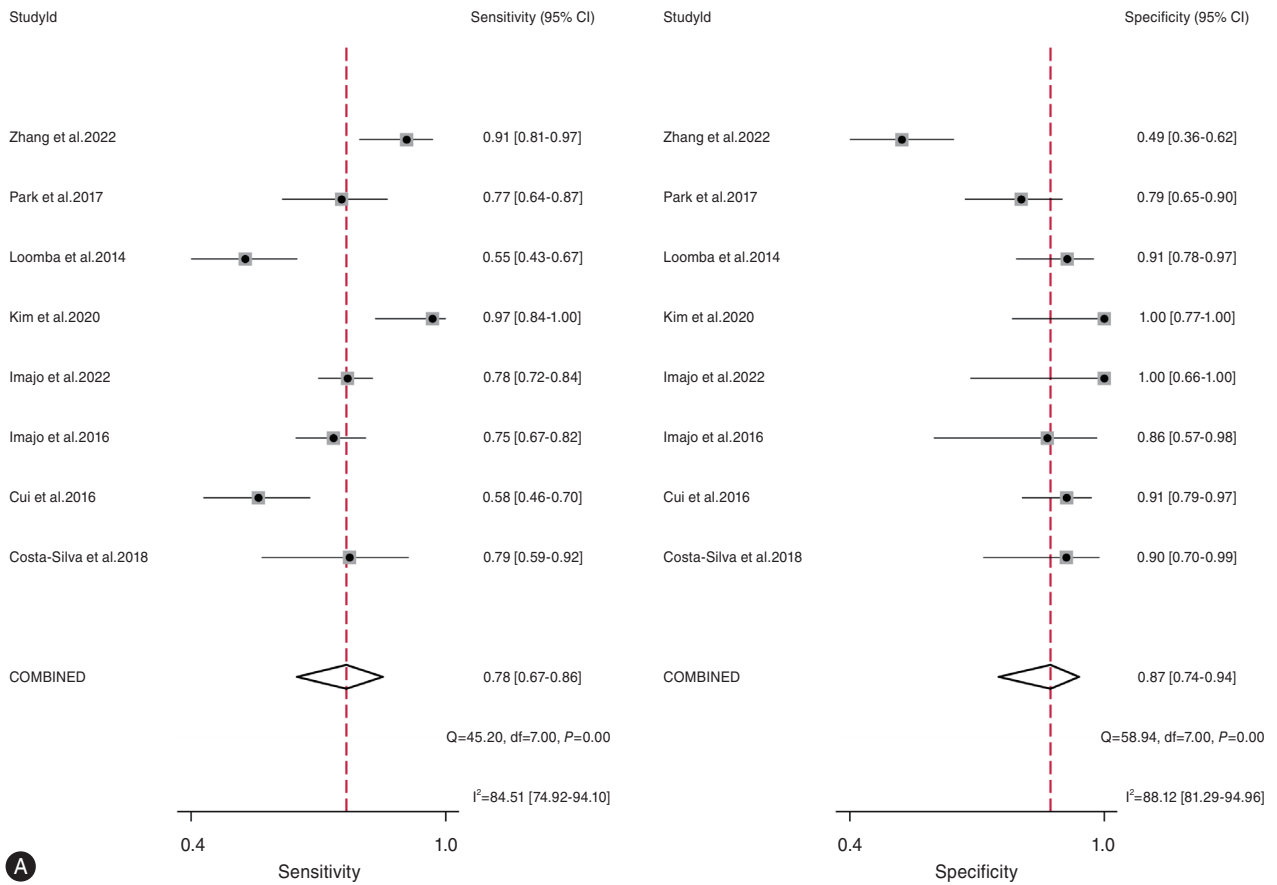


Supplementary Figure 3. Funnel plots of VCTE for assessing fibrosis stages (A) \geq F1, (B) \geq F2, (C) \geq F3, and (D) F4. VCTE, vibration-controlled transient elastography.



Supplementary Figure 4. Forrest plots of MRE for assessing fibrosis stages (A) $\geq F1$, (B) $\geq F2$, (C) $\geq F3$, and (D) F4. MRE, magnetic resonance elastography.