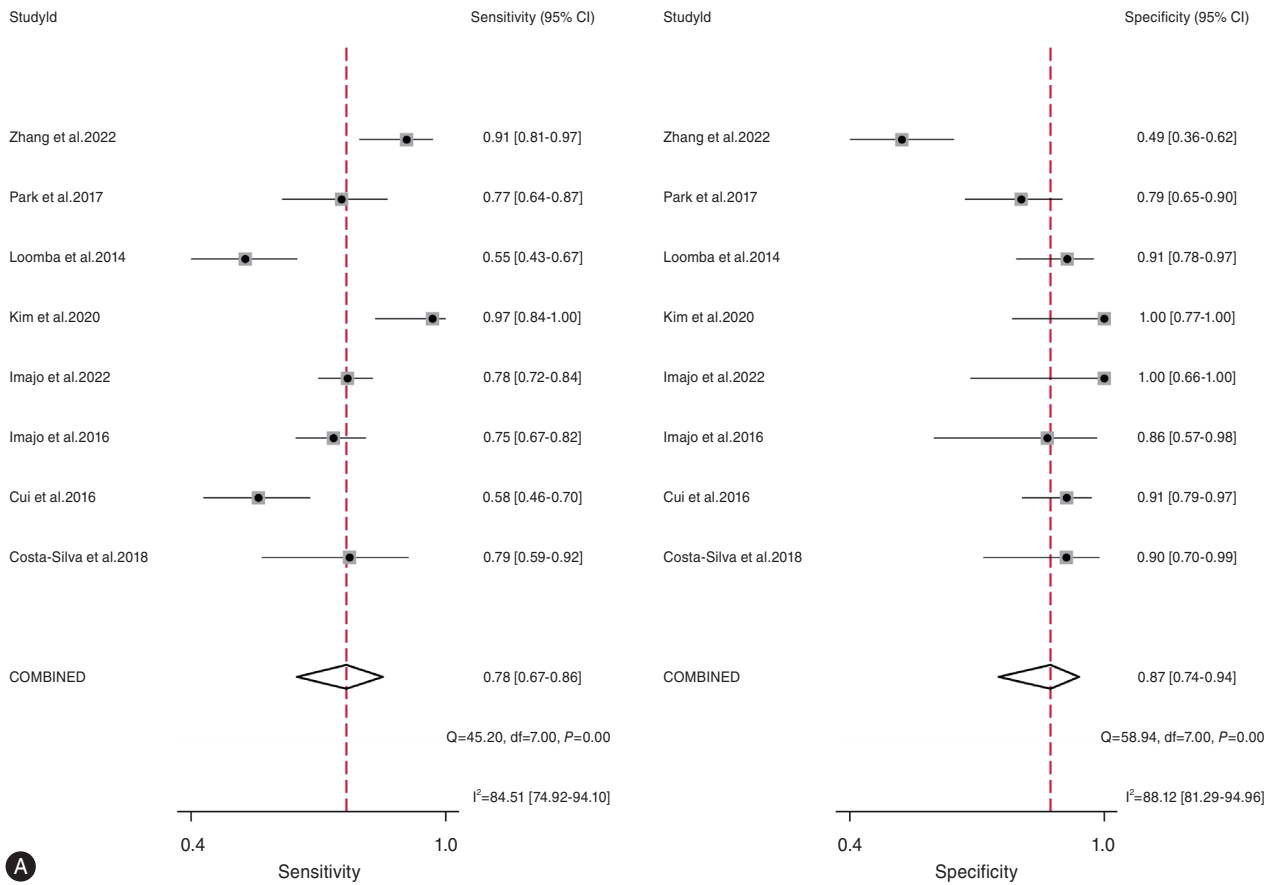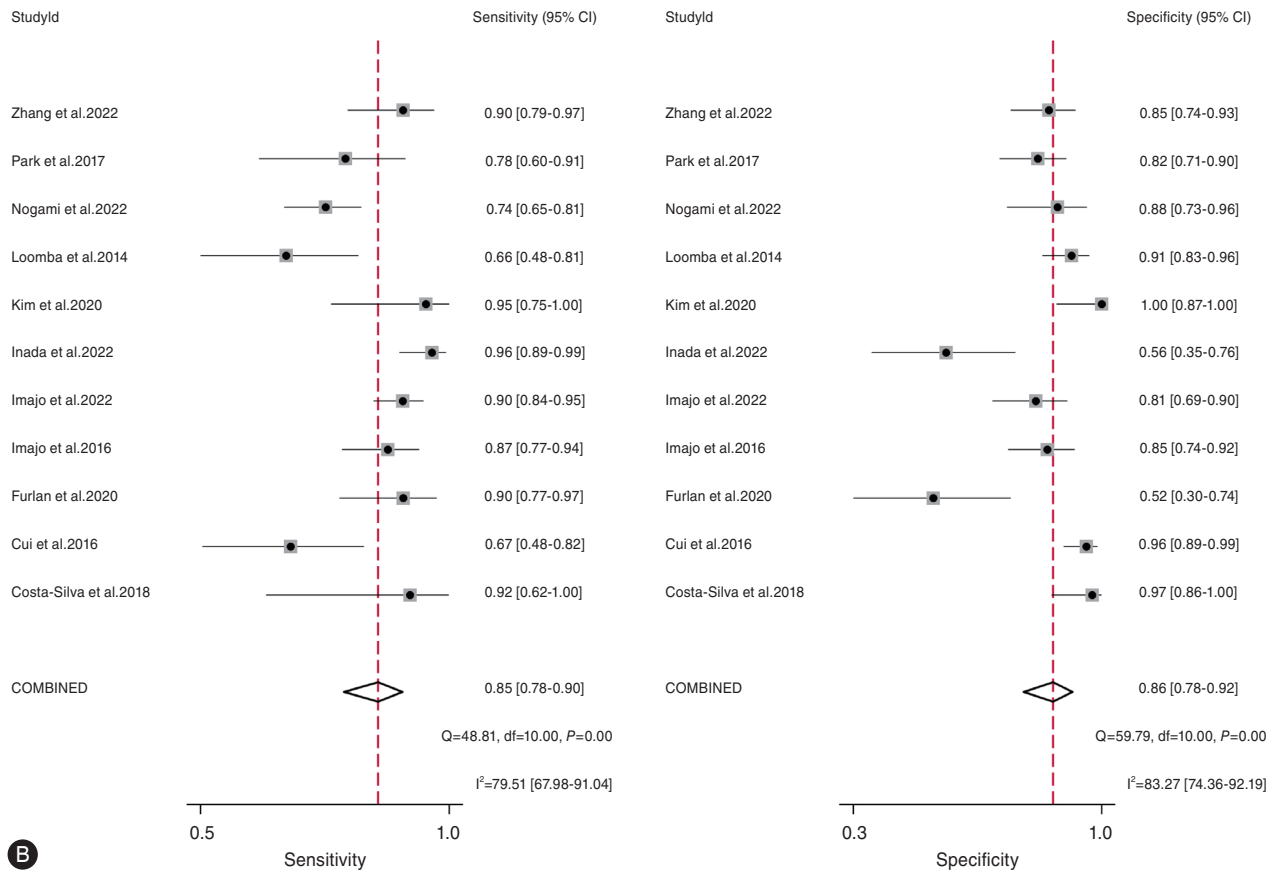
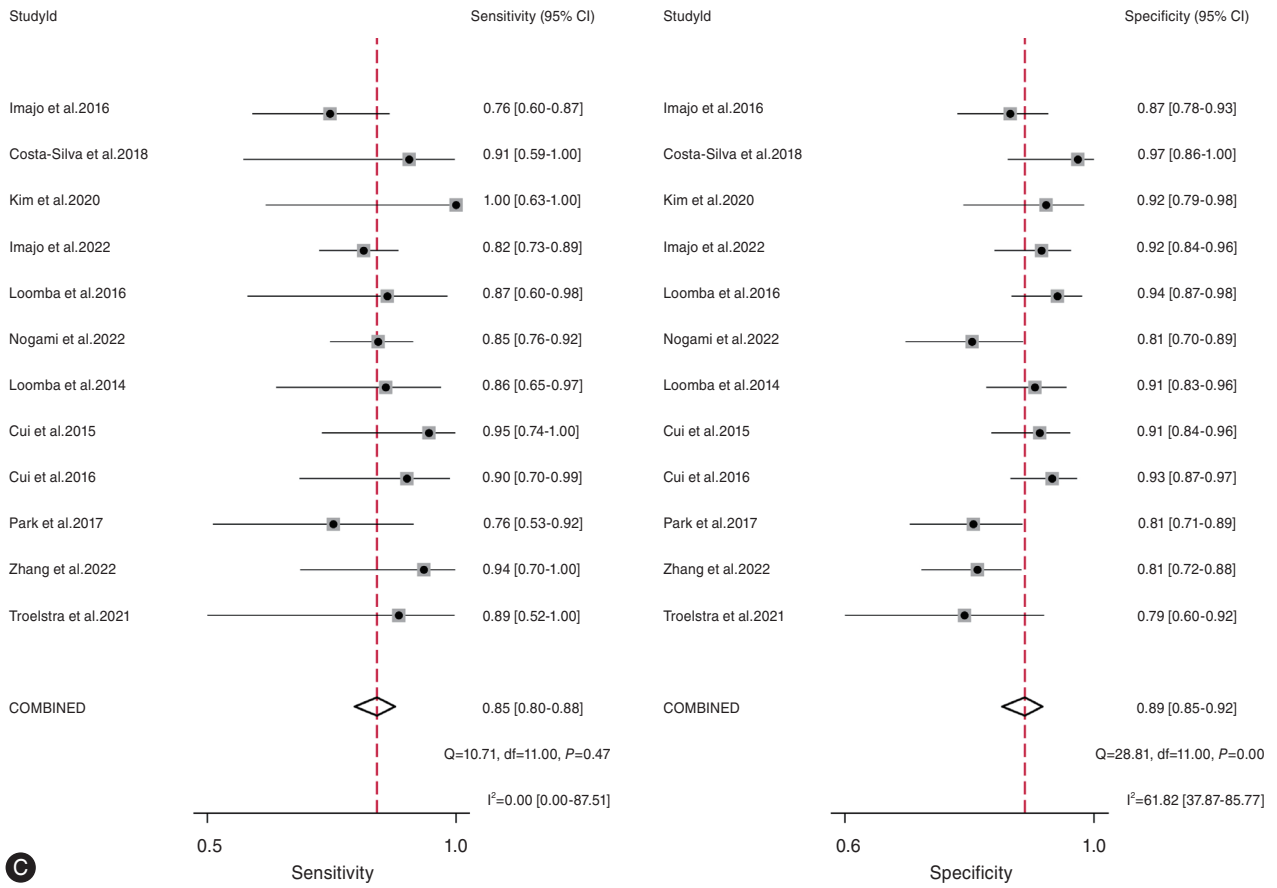


Supplementary Figure 4. Forrest plots of MRE for assessing fibrosis stages (A) $\geq F1$, (B) $\geq F2$, (C) $\geq F3$, and (D) F4. MRE, magnetic resonance elastography.

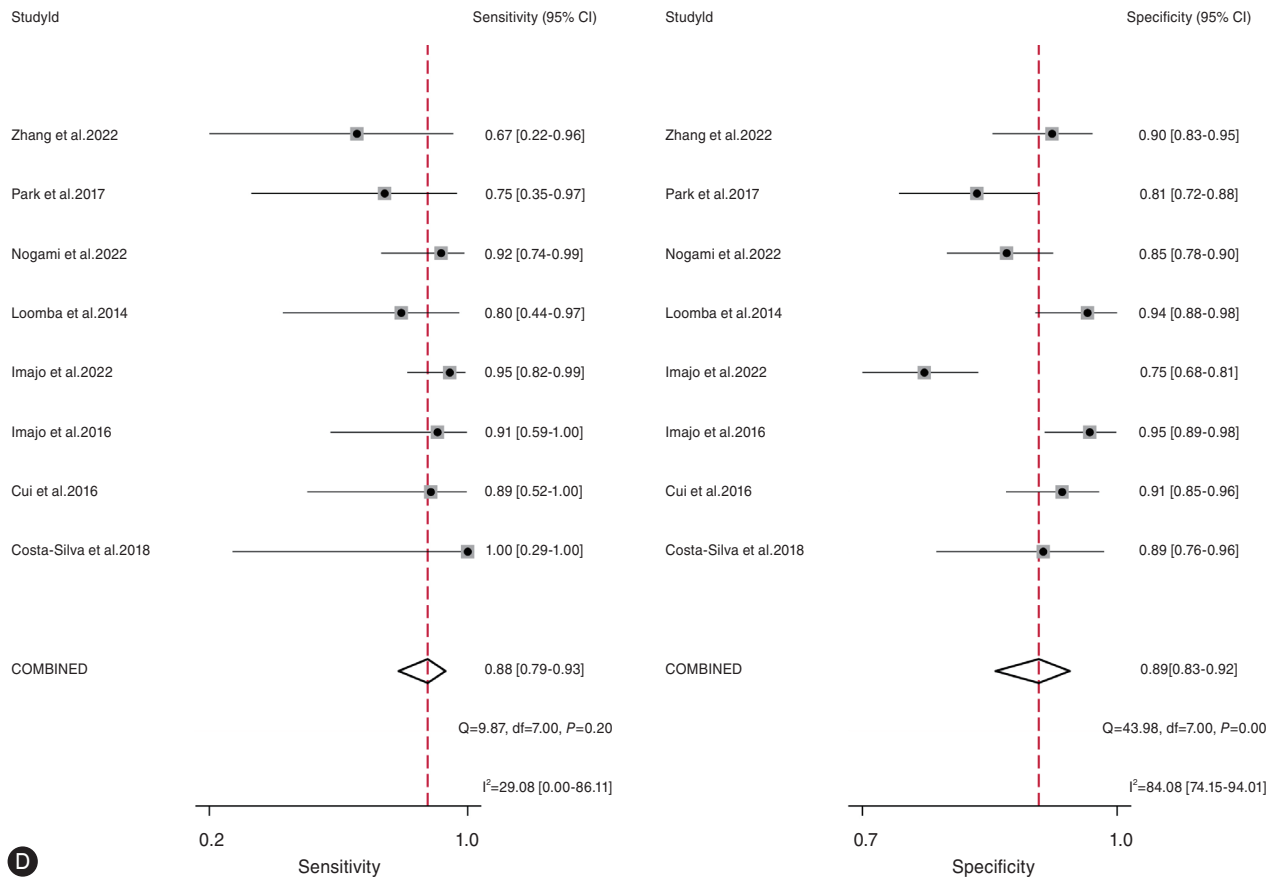


B Supplementary Figure 4. Continued.



©

Supplementary Figure 4. Continued.



D

Supplementary Figure 4. Continued.